



SLIMS,PONDICHERRY



Date 09/05/2019

From

DR.R.CHIDHAMBARAM ,
Professor and Head,
Dept.of radio-diagnosis and Imaging Sciences ,
SLIMS,PONDICHERRY
Bharath Institute of Higher Education and Research,
Chennai.

To

The Dean,
SLIMS
Bharath Institute of Higher Education and Research,
Chennai.

Sub: Permission to conduct value-added course:

CLINICO-RADIOLOGICAL CORRELATION IN CXR

Dear Sir,

With reference to the subject mentioned above, the department proposes to conduct a value-added course titled **CLINICO-RADIOLOGICAL CORRELATION IN CXR** on 28/12/19. We solicit your kind permission for the same.

Kind Regards.

DR.R.CHIDHAMBARAM

FOR THE USE OF DEANS OFFICE

Names of Committee members for evaluating the course:


The Dean: Dr . K . Balagunmathan

The HOD: Dr . R . Chidhambaram

The Expert: Dr . S.iva subramanian.

The committee has discussed about the course and is approved.

Dean 
(Sign & Seal)


Subject Expert
(Sign & Seal)

HOD 
(Sign & Seal)

DEAN
SRI LAKSHMI NARAYANA INSTITUTE OF MEDICAL SCIENCES
OSUDU, AGARAM VILLAGE,
KODAPAKKAM POST,
PUDUCHERRY - 605 502

BIHER

M. SIVASUBRAMANIYAN, DNB.,
Reg. No: 88846
Asst. Professor Radiology
Sri Lakshmi Narayana Institute of Medical Sciences
Osudu, Kudapakkam, Puducherry-605 502.

DEPARTMENT OF RADIOLOGY
SRI LAKSHMINARAYANA
INSTITUTE OF MEDICAL SCIENCE
PUDUCHERRY - 605 002.

SLIMS

Course Proposal

Course Title: CLINICO-RADIOLOGICAL CORRELATION IN CXR

CourseObjective: TO DEMONSTRATE CLINICO-RADIOLOGICAL CORRELATION IN CXR

CourseOutcome: BETTER UNDERSTANDING OF CLINICO-RADIOLOGICAL CORRELATION IN CXR

Course Audience: ANY MEDICAL STUDENT

Course Coordinator: PROF.DR.R.CHIDHAMBARAM,M.B.B.S.,MDRD.,

Course Faculties with Qualification and Designation:

- 1. DR. R.CHIDHAMBARAM,MBBS,MDRD.PROF. AND HOD**
- 2. DR.MOHAMAD HASSAN,MBBS,MDRD,ASST PROFESSOR**
- 3. DR.JYOTI BASU,MBBS,DNB,SENIOR RESIDENT**

Course Curriculum/Topics with schedule (Min of 30 hours)-ENCLOSED

| SINo | Date | Topic | Time | Hours |
|------|------------|----------------------------------|-------------|---------|
| 1 | 21-09-2019 | INTRO | 2:00 PM | 2 hours |
| 2 | 22-09-2019 | PRINCIPLES OF CXR INTERPRETATION | 2:00 PM | 2 hours |
| 3 | 23-09-2019 | BASIC PHYSICAL EXAMINATION-CHEST | 2:00 PM | 2 hours |
| 4 | 24-09-2019 | LUNG CONSOLIDATION RIGHT LUNG | 2:00 PM | 2 hours |
| 5 | 25-09-2019 | LUNG CONSOLIDATION LEFT LUNG | 2:00 PM | 2 hours |
| 6 | 26-09-2019 | LUNG COLLAPSE –RIGHT SIDE | 2:00 PM | 2 hours |
| 7 | 27-09-2019 | LUNG COLLAPSE – LEFT SIDE | 2:00 PM | 2 hours |
| 8 | 28-09-2019 | PULMONARY TUBERCULOSIS | 2:00 PM | 2 hours |
| 9 | 29-09-2019 | PLEURAL EFFUSION -MILD | 2:00 PM | 2 hours |
| 10 | 30-09-2019 | PNEUMOTHORAX | 2:00 PM | 2 hours |
| 11 | 01-10-2019 | HYDROPNEUMOTHORAX | 2:00 PM | 2 hours |
| 12 | 02-10-2019 | PLEURAL EFFUSION-MODERATE | 2:00 PM | 2 hours |
| 13 | 03-10-2019 | WHITE WASH ONE SIDE | 2:00 PM | 2 hours |
| 14 | 04-10-2019 | BRONCHIECTASIS | 2:00 PM | 2 hours |
| 15 | 05-10-2019 | QUIZ | 2:00 PM | 2 hours |
| | | | Total Hours | 30 |

REFERENCE BOOKS: (Minimum 2)

1.CXR MADE EASY

2. MADE EASY

BIHER

SLIMS



OFFICE OF THE DEAN

Sri Lakshmi Narayana Institute of Medical Sciences

OSUDU, AGARAM VILLAGE, VILLIANUR COMMUNE, KUDAPAKKAM POST,
PUDUCHERRY - 605 502.

[Recognised by Medical Council of India, Ministry of Health letter No. U/12012/249/2005-ME (P -II) dt. 11/07/2011]
[Affiliated to Bharath University, Chennai - TN]

Circular

21.05.2019

Sub: Organising Value-added Course: reg

With reference to the above mentioned subject, it is to bring to your notice that Sri Lakshmi Narayana Institute of Medical Sciences, **Bharath Institute of Higher Education and Research** is organizing “**Clinical Radiological correlation of CXR**”. The course content and registration form is enclosed below.”

The application must reach the institution along with all the necessary documents as mentioned. The hard copy of the application should be sent to the institution by registered/ speed post only so as to reach on or before May to June 2019. Applications received after the mentioned date shall not be entertained under any circumstances.



Dean

DEAN
SRI LAKSHMI NARAYANA INSTITUTE OF MEDICAL SCIENCES
OSUDU, AGARAM VILLAGE,
KODAPAKKAM POST,
PUDUCHERRY - 605 502

BIHER

SLIMS

VALUE ADDED COURSE

1. Name of the programme & Code :

Clinical correlation in chest xray

RAD 11

2. Duration & Period

30 hrs & September 2019– January 2020 & February20 – August 2020

3. Information Brochure and Course Content of Value Added Courses

Enclosed as Annexure- I

4. List of students enrolled

Enclosed as Annexure- II

5. Assessment procedures:

Multiple choice questions- *Enclosed as Annexure- III*

6. Certificate model

Enclosed as Annexure- IV

7. No. of times offered during the same year:

September 2019– January 2020 & February20 – August 2020

8. Year of discontinuation: 2020

9. Summary report of each program year-wise

| Value Added Course- September 2019 - August 2020 | | | | | |
|--|-------------|------------------------------------|-------------------|-----------------|-----------------|
| Sl. No | Course Code | Course Name | Resource Persons | Target Students | Strength & Year |
| 1 | RAD 11-1 | Clinical correlation in chest xray | Dr.Jothibas | MBBS | 20 (Sep – Jan) |
| 2 | RAD 11-2 | Clinical correlation in chest xray | Dr.Mohamed Hassan | MBBS | 20 (Feb- Aug) |

10. Course Feed Back

Enclosed as Annexure- V


RESOURCE PERSON


DEPARTMENT OF RADIOLOGY,
SRI LAKSHMINARAYANA
INSTITUTE OF MEDICAL SCIENCE
PUDUCHERRY - 605 002.


COORDINATOR

DEPARTMENT OF RADIOLOGY,
SRI LAKSHMINARAYANA
INSTITUTE OF MEDICAL SCIENCE
PUDUCHERRY - 605 002.

BIHER

SLIMS



Sri Lakshmi Narayana Institute of Medical Sciences

Affiliated to Bharath Institute of Higher Education & Research
(Approved to the University under section 3 of the UGC Act 1956)



CERTIFICATE OF MERIT


This is to certify that B.MOHAN has actively participated in the Value Added Course on **CLINICAL CORRELATION IN CHEST XRAY** held during **September 2019- January 2020** Organized by Sri Lakshmi Narayana Institute of Medical Sciences, Pondicherry-605 502, India.

Dr. Jothibas

RESOURCE PERSON

Dr. Chidhambaram

COORDINATOR



Sri Lakshmi Narayana Institute of Medical Sciences

Affiliated to Bharath Institute of Higher Education & Research
(Approved to the University, under section 3 of the UGC Act 1956)



CERTIFICATE OF MERIT

This is to certify that MERLIN S has actively participated in the Value Added Course on **CLINICAL CORRELATION IN CHEST XRAY** held during **February 20 – August 2020** Organized by Sri Lakshmi Narayana Institute of Medical Sciences, Pondicherry- 605 502, India.

Dr. Mohamed Hassan

RESOURCE PERSON

Dr. Chidhambaram

COORDINATOR

TOPIC:- VALUE ADDED COURSE
Clinical Correlation in Chest-X ray

List of Students Enrolled:

| 1ST YEAR MBBS STUDENTS | | | |
|------------------------|---------------------------------|---------------------|-----------|
| SL.NO. | NAME OF THE STUDENT | UNIVERSITY REG. NO. | signature |
| 1 | KAVITHA .M | U16MB311 | |
| 2 | KAVIYA .K | U16MB312 | |
| 3 | KEERTHANA .K | U16MB313 | |
| 4 | KEERTHI K DAS | U16MB314 | |
| 5 | KUNCHAL BALA VENKATA RAMANA RED | U16MB315 | |
| 6 | LAKSHMIPURAM VEDA SREEVIDYA | U16MB316 | |
| 7 | LOGESH BABU .S | U16MB317 | |
| 8 | LOKESHWARAN .M | U16MB318 | |
| 9 | MADHUMITHA .R | U16MB319 | |
| 10 | MADHUMITHA .S | U16MB320 | |
| 11 | MANIMAAARANE .R | U16MB321 | |
| 12 | MATHIVAANANE .R | U16MB322 | |
| 13 | MATHIVANAN .J | U16MB323 | |
| 14 | MD ALTAF KHAN | U16MB324 | |
| 15 | MERALA CHARAN CROWDARY | U16MB325 | |
| 16 | MERLINS | U16MB326 | |
| 17 | MERLINE SHEEBA .B | U16MB327 | |
| 18 | MOHAN .B | U16MB328 | |
| 19 | MOHIT BHARDWAJ | U16MB329 | |
| 20 | MONISH PALEI PATRA | U16MB330 | |
| 21 | MONISHA . S | U16MB331 | |
| 22 | MONISHA .M | U16MB332 | |
| 23 | MONISHDEVI .N | U16MB333 | |
| 24 | MOUNIKA .A | U16MB334 | |
| 25 | MOUNIKA.B | U16MB335 | |
| 26 | MUHAMMAD SHEBIN | U16MB336 | |
| 27 | MUSKAAN SHAMIM | U16MB337 | |
| 28 | MUSULURI SHYAM SINDHU | U16MB338 | |
| 29 | NAMITA YADAV | U16MB339 | |
| 30 | NAMRATA GHORAI | U16MB340 | |


RESOURCE PERSON

COORDINATOR

Annexure II

BIHER

SLIMS



BIHER

SLIMS

Student Feedback Form

Course Name: CLINICAL CORRELATION IN CHEST X RAY

Subject Code: MC11

Name of Student: CHA. R Roll No.: U16MB332

We are constantly looking to improve our classes and deliver the best training to you. Your evaluations, comments and suggestions will help us to improve our performance.

| Sl. No | Particulars | 1 | 2 | 3 | 4 | 5 |
|--------|---|---|---|---|---|---|
| 1 | Objective of the course is clear | | | | | |
| 2 | Course contents met with your expectations | | | | | |
| 3 | Lecturer's experience was well planned | | | | | |
| 4 | Lectures were clear and easy to understand | | | | | |
| 5 | Teaching aids were effective | | | | | |
| 6 | Instructor's knowledge, interpretation and were helpful | | | | | |
| 7 | Overall rating of the course | | | | | |

Suggestions if any:

Good

Date:

[Signature]

Student Feedback Form

Course Name: CLINICAL CORRELATION IN CHEST X RAY

Subject Code: MC11

Name of Student: Sudh. Kumar Roll No.: U16MB387

We are constantly looking to improve our classes and deliver the best training to you. Your evaluations, comments and suggestions will help us to improve our performance.

| Sl. No | Particulars | 1 | 2 | 3 | 4 | 5 |
|--------|---|---|---|---|---|---|
| 1 | Objective of the course is clear | | | | | |
| 2 | Course contents met with your expectations | | | | | |
| 3 | Lecturer's experience was well planned | | | | | |
| 4 | Lectures were clear and easy to understand | | | | | |
| 5 | Teaching aids were effective | | | | | |
| 6 | Instructor's knowledge, interpretation and were helpful | | | | | |
| 7 | Overall rating of the course | | | | | |

Suggestions if any:

well information

Date:

[Signature]

CHEST QUESTIONS

10

1. Regarding the imaging modalities of the chest:

- (a) High resolution computed tomography (HRCT) uses a slice thickness of 4-6 mm to identify mass lesions in the lung.
- (b) Spiral CT ensures that no portion of the chest is missed due to variable inspiratory effort.
- (c) MRI shows excellent detail of the lung anatomy.
- (d) Bronchography is the technique of choice to visualize the bronchial tree.
- (e) CT pulmonary angiography (CTPA) is performed using catheters placed in a femoral vein.

2. Regarding the development of the lung:

- (a) The tracheobronchial groove appears on the ventral aspect of the caudal end of the pharynx.
- (b) The primary bronchial buds develop from the tracheobronchial diverticulum.
- (c) The epithelium lining the alveoli is the same before and after birth.
- (d) A persistent tracheo-oesophageal fistula (TOF) is commonly associated with an atresia of the duodenum.
- (e) Uni-lateral pulmonary hypoplasia is usually due to a congenital diaphragmatic hernia.

3. Regarding the blood supply to the chest wall:

- (a) The posterior intercostal arteries supply the 11 intercostal spaces.
- (b) The internal thoracic artery arises from the subclavian artery and supplies the upper six intercostal spaces.
- (c) The neurovascular bundle passes around the chest wall in the subcostal groove deep to the internal intercostal muscle.
- (d) The intercostal spaces are drained by two anterior veins and a single posterior intercostal vein.
- (e) The posterior intercostal vein drains into the internal thoracic vein.

4. Regarding the azygos venous system:

- (a) The azygos vein at the level of the fourth thoracic vertebra arches over the root of the right lung to end in the superior vena cava (SVC).
- (b) About 10% of the population have an azygos lobe.
- (c) The thoracic duct and aorta are to the right of the azygos vein.
- (d) The second, third and fourth intercostal spaces on the right, drain via the right superior intercostal vein into the azygos vein.
- (e) In congenital absence of IVC the azygos vein enlarges.

5. Regarding the hemiazygos and accessory hemiazygos venous systems:

- (a) The hemiazygos vein at the level of the fourth thoracic vertebra crosses the vertebral column behind the aorta, oesophagus and thoracic duct.
- (b) The ascending lumbar veins and the lower three posterior intercostal veins are the tributaries of the hemiazygos vein.
- (c) The accessory hemiazygos vein receives the fourth to the eighth intercostal veins on the left.
- (d) The accessory hemiazygos vein may drain into the left brachiocephalic vein.
- (e) The first posterior intercostal vein may drain into the corresponding vertebral vein.

6. Regarding the airways:

- (a) In adults the right main-stem bronchus is steeper than the left.
- (b) The left main bronchus is about twice as long as the right.
- (c) The bronchioles contain cartilage.
- (d) Gas exchange takes place in the terminal bronchioles and acini.
- (e) The bronchopulmonary segments are based on the pulmonary arterial system.

7. Regarding the secondary pulmonary lobule:

- (a) It consists of approximately ten acini.
- (b) The lobular vein follows the branches of the bronchioles.
- (c) Lymph drainage is both interlobular and central along the arteries.
- (d) Lobules are best demonstrated nearer to the hilum of the lung on CT.
- (e) The interlobular septa are seen usually on conventional CT.

8. Regarding the pulmonary blood vessels:

- (a) The bronchovascular bundle of the secondary pulmonary lobule is demonstrated as a rounded density about 1 cm away from the pleural border on axial CT.
- (b) The inferior pulmonary veins draining the lower lobes are more vertical than the lower lobe arteries.
- (c) The upper lobe veins lie lateral to the arteries.
- (d) In a frontal chest radiograph the artery and bronchus of the anterior segment of the upper lobes are frequently seen end-on.
- (e) The left pulmonary artery passes anterior to the left main bronchus.

9. Regarding the pleura:

- (a) The parietal pleura is continuous with the visceral pleura at the hilum.
- (b) On a PA radiograph the pleura is seen in the costophrenic sulcus.
- (c) The parietal pleura is supplied by the pulmonary circulation.
- (d) The fissures usually contain a layer of parietal and visceral pleura.
- (e) The intercostal stripe is seen on axial CT as a linear opacity of soft tissue density at the intercostal space.

10. Regarding the fissures of the lung:

- (a) Complete fissures may be crossed by small bronchovascular structures seen on HRCT.
- (b) The oblique fissure separates the upper and lower lobes from the middle lobe on the right.
- (c) The lateral and medial portion of the oblique fissure are equidistant from the anterior chest wall.
- (d) The major fissures appear as a soft tissue linear density from the hilum to the chest wall on standard 10 mm thick CT sections.
- (e) The minor fissure separates the right middle lobe from the right lower lobe.

Date: 09/05/2019

From

Dr.R.Chidhambaram
Professor and Head,
Department of Radiology,
Sri Lakshmi Narayana Institute of Medical Sciences
Bharath Institute of Higher Education and Research,
Chennai.

Through Proper Channel

To

The Dean,
Sri Lakshmi Narayana Institute of Medical Sciences
Bharath Institute of Higher Education and Research,
Chennai.

**Sub: Completion of value-added course: CLINICO-RADIOLOGICAL
CORRELATION IN CXR**

Dear Sir,

With reference to the subject mentioned above, the department has conducted the value-added course titled: : CLINICO-RADIOLOGICAL CORRELATION IN CXR for 20 medical student (batch 2) .

We solicit your kind action to send certificates for the participants, that is attached with this letter. Also, I am attaching the photographs captured during the conduct of the course.

Kind Regards,

Dr.R.CHIDHAMBARAM



DEPARTMENT OF RADIOLOGY
SRI LAKSHMINARAYANA
INSTITUTE OF MEDICAL SCIENCE
PUDUCHERRY - 605 002.

Encl: Certificates

Photographs

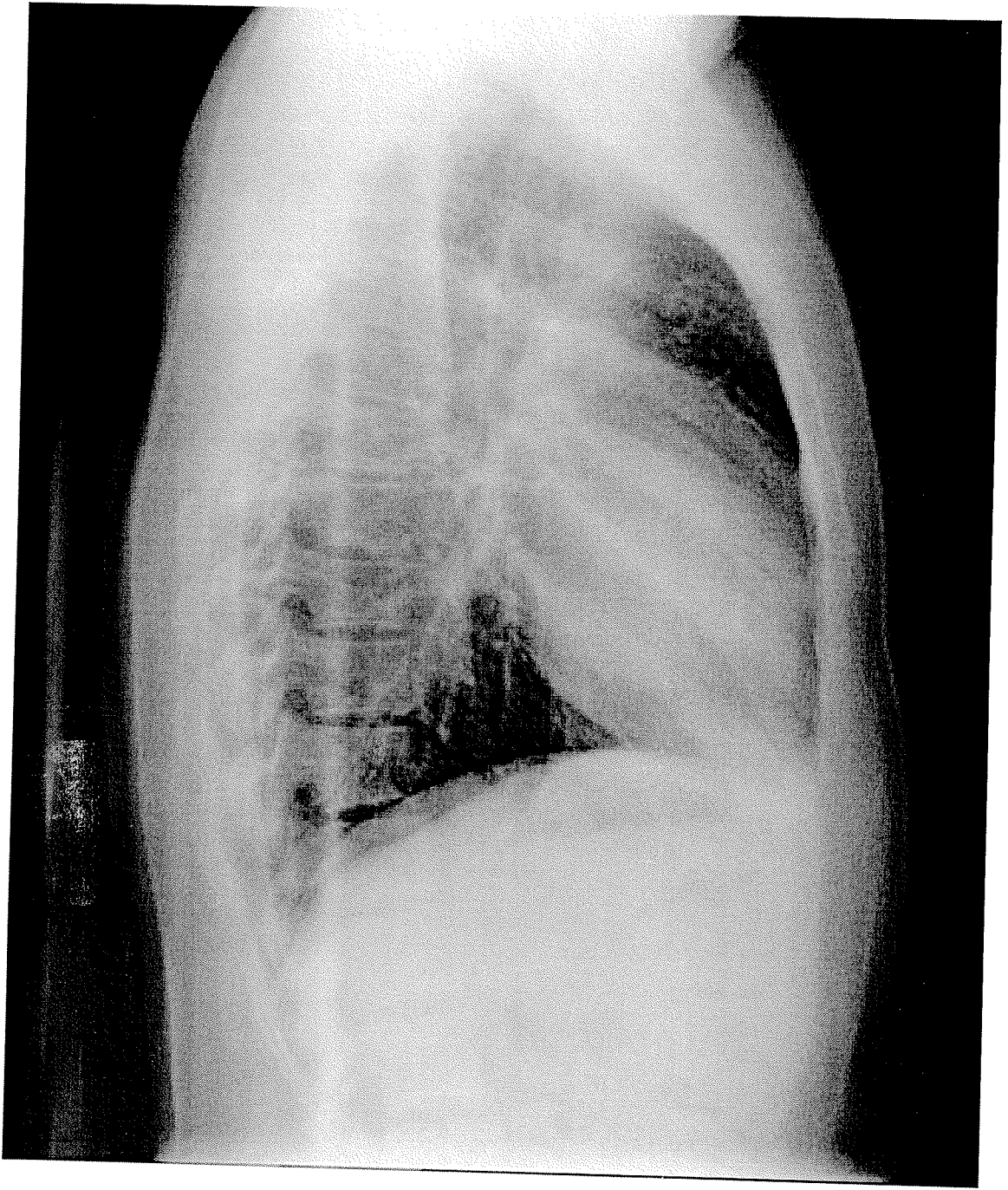
SRI LAKSHMI NARAYANA
INSTITUTE OF MEDICAL SCIENCES
DEPARTMENT OF RADIOLOGY AND IMAGING SCIENCES

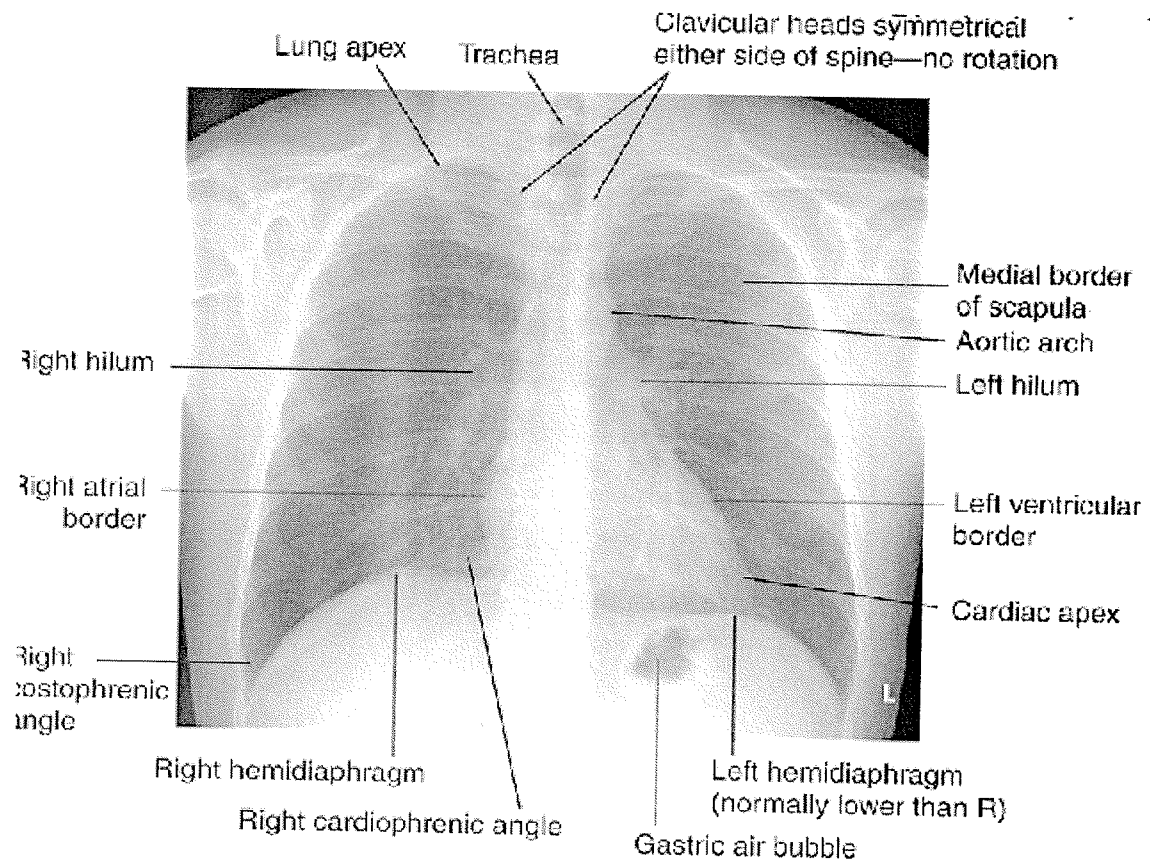
CLINICAL CORRELATION

IN CHEST X-RAY

COURSE CONTENTS

- 1.) *Clinical features & Radiological findings of Pneumothorax*
- 2.) *Clinical features & Radiological findings of Pleural effusion*
- 3.) *Clinical features & Radiological findings of Consolidation*





VENUE:

LECTURE HALL 1

TIME : SATURDAY 2.00 TO 4 .00 PM.